

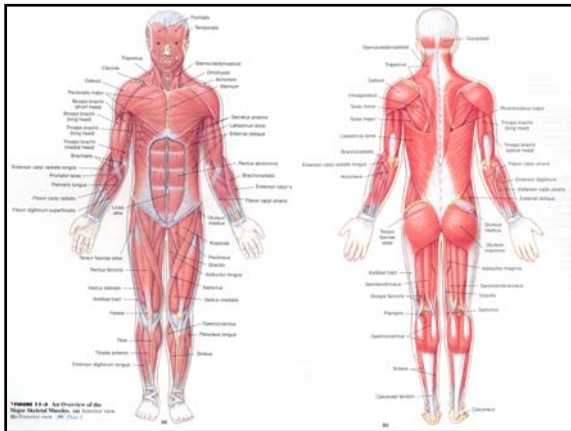
Muscular System

The Anatomy of the Muscular System

- Approximately 700 skeletal muscles have been identified.

Two factors interact to determine the effect of muscle contraction

1. the anatomical arrangement of muscle fibers
2. the way the muscle attaches to the skeleton



Organization of Skeletal Muscle Fibers

- Muscle fibers within a skeletal muscle form bundles called **fascicles**. The muscle fibers in the fascicles are arranged in four basic patterns of organization.

1. Parallel Muscles

- In parallel muscle, the fascicles are parallel to the long axis of the muscle.

- Most skeletal muscles are parallel muscles

- Some are flat bands with broad attachments (aponeuroses) at each end

- Some are plump and cylindrical with tendons at one or both ends. These muscles are spindle-shaped with a central **body** (aka: **belly or gaster**). An example is the biceps brachii (when it contracts it gets shorter and larger in the middle).

- A skeletal muscle can contract effectively until it has shortened by about 30%.

- A parallel muscle 1 in² in diameter can develop approx. 50 lbs. of tension.

2. Convergent Muscles

- In a convergent muscle, the fibers are based over a broad area, but all the fibers come together at a common attachment site.
- They may pull on a tendon, a tendinous sheet, or a slender band of collagen fibers called a **raphe**.
- The fibers typically spread out in a fan shape with a tendon at the apex.

- Chest muscles (of the pectoralis group) are examples.

- Advantage of this pattern is that a single pull on the tendon can get tension in several directions.

- One disadvantage of this pattern is that muscles cannot develop as much tension as a parallel muscle.

3. Pennate Muscle (penna refers to a feather)

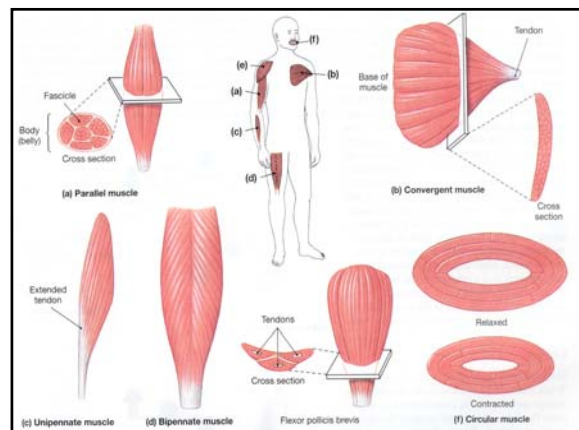
- In a pennate muscle the fascicles form a common angle with the tendon and the muscle takes on the shape of a feather at the apexes.
- Because they pull at an angle, pennate muscles don't move their tendons as far as parallel muscles, BUT, they produce more tension than parallel muscles of the same diameter (more fibers).
- If all the fibers are on the same side of the tendon then its **unipennate**
(i.e.-the *extensor digitorum* that extends the finger)

- More commonly, pennate muscles have fibers on each side of the tendon. This is a **bipennate** muscle.
(i.e.- the *rectus femoris* that extends the knee joint)

- If the tendon branches within a pennate muscle, the muscle is said to be **multipennate**.
(i.e.- the triangular *deltoid* shoulder muscle).

4. Circular Muscle

- In a circular muscle (aka-**sphincter**) the openings are concentrically arranged around an opening or recess.
- When the muscle contracts, the diameter of the opening decreases.
- Circular muscles guard entrances and exits of internal passageways such as the digestive and urinary tracts (i.e.- the *obicularis oris*).



Skeletal Muscle Length-Tension Relationships

- Skeletal muscles produce MAXIMUM tension over a relatively narrow range of sarcomere lengths.
- Usually the amount of tension produced in a contraction varies with the resting sarcomere lengths.
- Over a full range of motion (full extension to full flexion), tension produced rises and falls. While doing curls, you move your elbow from full extension to full flexion, with a weight in your hand.
- The flexion is hard to begin with, becomes easier at midrange, and then more difficult again as the movement nears completion.

Group Work:

- For complex movements, muscles usually work in groups , rather than individually.
- Shorter starter muscles begin the movement. When these start muscles are at their max. tension, the prime muscle sarcomeres are at their minimum tension length.

Levers

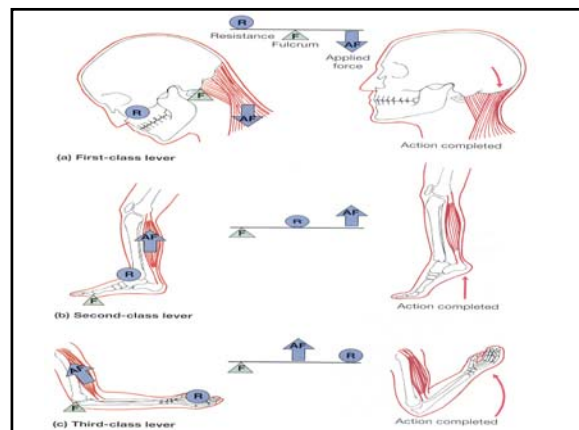
- Skeletal muscles usually don't work in isolation. They use bones they attach to for levers systems to help accomplish movement. A lever is a rigid structure (like a bone) that moves on a fixed point called a fulcrum.
- In the body each bone is a lever, and each joint is a fulcrum.

Levers can change:

1. the direction of an applied force
2. the distance and speed of movement produced by an applied force
3. the effective strength of an applied force

Three classes of levers are found in the human body:

- **First Class Levers** are like see-saws. In first class levers, the resistance and applied force are on opposite sides of the fulcrum (i.e.- neck joint at the atlas).
- In **Second Class Levers**, the resistance is between the fulcrum and the applied force (i.e.- performing plantarflexion).
- **Third Class Levers** are the most common lever class in the body. With third class levers, the applied force is between the fulcrum and the resistance (i.e.- the *biceps brachii* and the elbow).



Muscle Terminology

TABLE 11-1 Muscle Terminology

Terms Indicating Direction Relative to Axes of the Body	Terms Indicating Specific Regions of the Body*	Terms Indicating Structural Characteristics of the Muscle	Terms Indicating Actions
Anterior (front)	Abdominis (abdomen)	Origin	General
Extimus (superficial)	Anconeus (elbow)	Biceps (two heads)	Abductor
Extrinsic (outside)	Auricularis (auricle of ear)	Triceps (three heads)	Adductor
Inferioris (inferior)	Brachialis (brachium)	Quadriceps (four heads)	Depressor
Internus (deep, internal)	Capitis (head)		Extensor
Intrinsic (inside)	Carpi (wrist)	Shape	Flexor
Lateralis (lateral)	Cervicis (neck)	Deltoid (triangle)	Levator
Medialis/medius (medial, middle)	Cleidoclavicular (clavicle)	Orbicularis (circle)	Pronator
Obliquus (oblique)	Coccygeus (coccyx)	Pectinate (comblike)	Rotator
Posterior (back)	Costalis (ribs)	Piriformis (pear-shaped)	Supinator
Profundus (deep)	Cutaneous (skin)	Platys- (flat)	Tensor
Rectus (straight, parallel)	Femoris (femur)	Pyramidal (pyramid)	
Superficialis (superficial)	Genio- (chin)	Rhomboides (rhomboid)	Specific
Superioris (superior)	Glossoglossal (tongue)	Serratus (serrated)	Buccinator (trumpeter)
Transversus (transverse)	Hallucis (great toe)	Splenius (bandage)	Risorius (laugher)
	Ilio- (ilium)	Teres (long and round)	Sartorius (like a tailor)
	Inguinal (groin)	Trapezius (trapezoid)	
	Lumbosacrus (lumbar region)		
	Nasalis (nose)	Other Striking Features	
	Nuchal (back of neck)	Alba (white)	
	Oculo- (eye)	Brevis (short)	
	Oris (mouth)	Gracilis (slender)	
	Palpebrae (eyelid)	Lata (wide)	
	Pollicis (thumb)	Latissimus (widest)	
	Popliteus (behind knee)	Longissimus (longest)	
	Psoas (loin)	Longus (long)	
	Radialis (radius)	Magnus (large)	
	Scapularis (scapula)	Major (larger)	
	Temporalis (temples)	Maximus (largest)	
	Thoracis (thoracic region)	Minimus (smallest)	
	Tibialis (tibia)	Minor (smaller)	
	Ulnaris (ulna)	-tendinosus (tendinous)	
	Uro- (urinary)	Vastus (great)	

Origins & Insertions

•Each muscle begins at an **origin**, ends at an **insertion**, and contract to perform a specific **action**.

In general:

- The origin remains stationary, the insertion moves
- The origin is proximal to the insertion
- The decision on the origin and the insertion is generally based on movement out of the anatomical position
- If movements can't tell the origin and insertion, the wide end of the muscle is considered the origin and the narrow end is the insertion.

Action

•A prime mover or **agonist** is a muscle whose contraction is chiefly responsible for producing a particular movement (*biceps brachii* is the prime mover responsible for flexion of the elbow).

•The **antagonist** is the prime mover whose actions oppose that of the agonist under consideration (the *triceps brachii* are the antagonist to the *biceps brachii*, responsible for extending of the elbow).

•Agonists and antagonists are functional opposites.

•**Synergists** and **fixators** are the helper muscles.

•**Synergists** help the prime movers accomplish a contraction.

•**Fixators** help stabilizing the origin of the agonist.

Axial & Appendicular Musculature

•The **axial musculature** arises on the axial skeleton; it positions the head and spinal column and moves the rib cage.

•The **appendicular musculature** stabilizes or moves components of the appendicular skeleton.

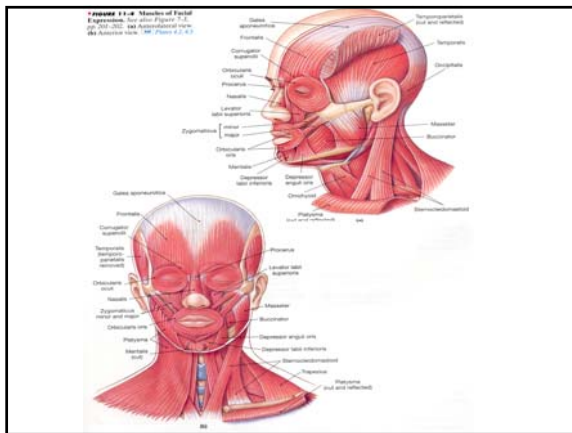
The Axial Muscles

•The axial muscles fall into logical groups on the basis of location, function, or both.

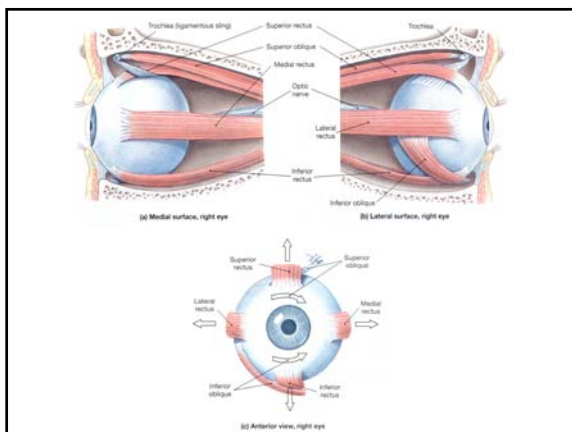
•**Innervation** refers to the identity of the nerve that controls a given muscle.

Muscles of the Head and Neck

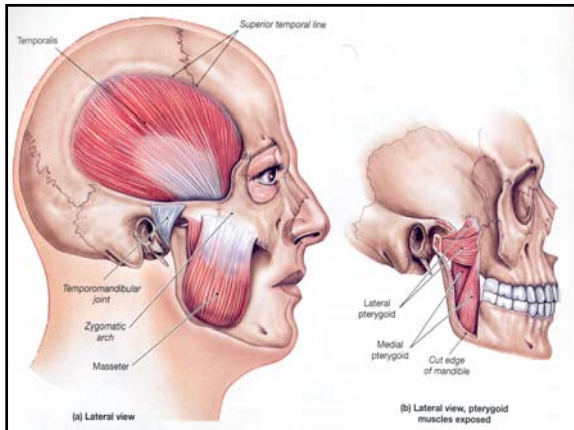
•The muscles of facial expression are the **orbicularis oris**, **buccinators**, **epicranius** (**frontalis** and **occipitalis**), and **platysma**.



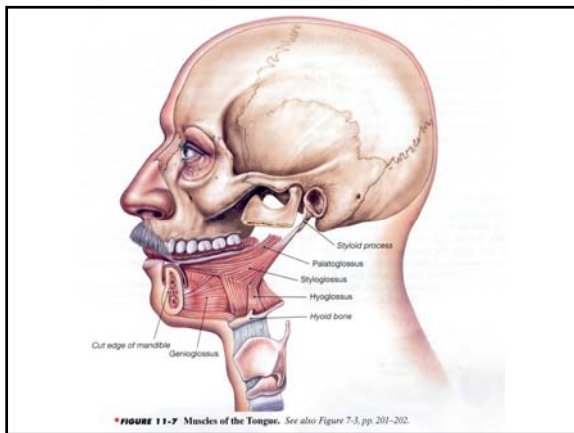
•Six **extrinsic eye muscles (oculomotor muscles)** control external eye movements: the **inferior** and **superior rectus**, **lateral** and **medial rectus**, and **inferior** and **superior obliques**.



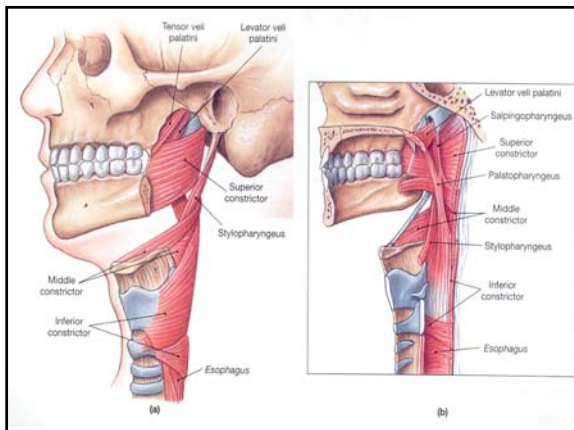
•The muscles of **mastication** (chewing) are the **masseter**, **temporalis**, and **pterygoid** muscles.



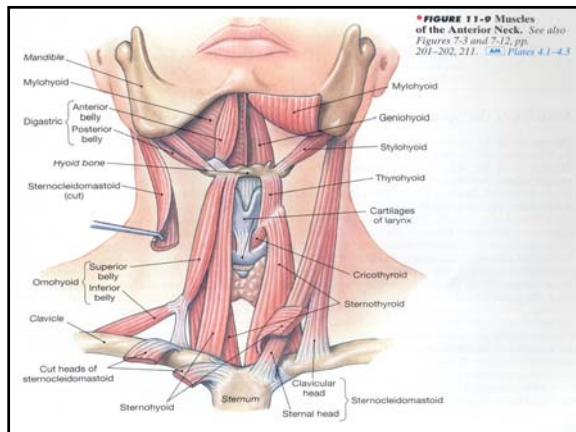
•The muscles of the tongue are necessary for speech and swallowing and assist in mastication. They are the **genioglossus**, **hyoglossus**, **palatoglossus**, and **styloglossus**.



•The muscles of the pharynx constrict the pharyngeal walls (**pharyngeal constrictors**), elevate the larynx (**laryngeal elevators**), and raise the soft palate (**palatal muscles**).



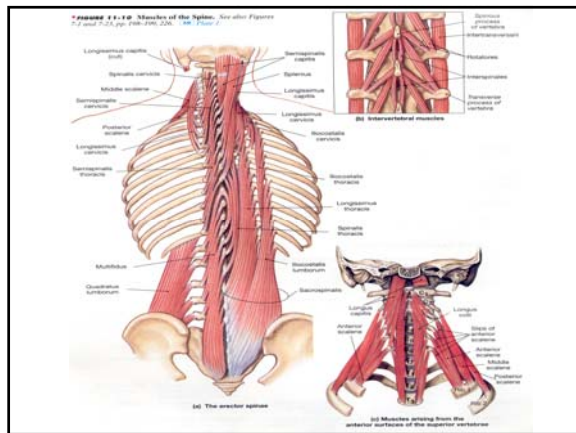
•The muscles of the neck control the position of the larynx, depress the mandible, and provide the foundation for the muscles of the tongue and pharynx.



Muscles of the Spine

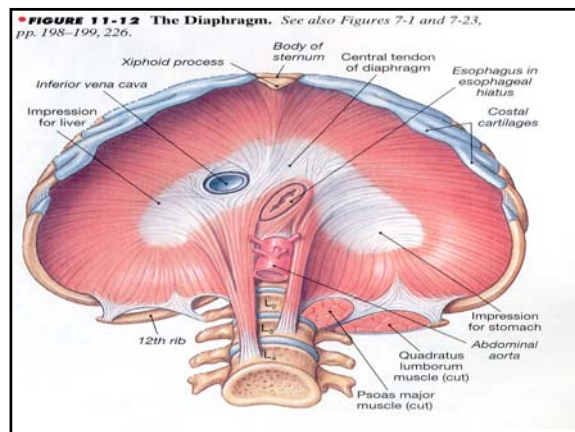
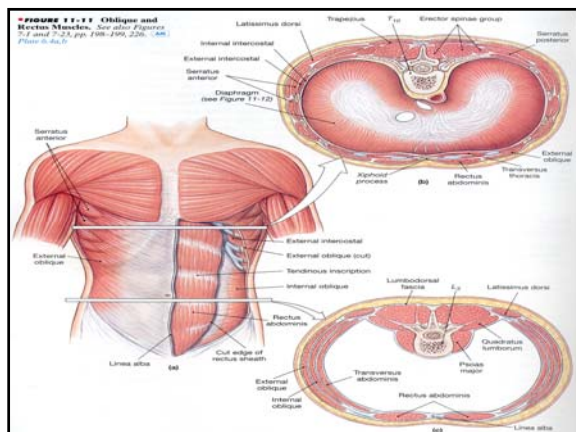
- The superficial muscles of the spine can be classified into the **spinalis**, **longissimus**, and **iliocostalis** divisions. In the lower lumbar and sacral regions the longissimus and iliocostalis are sometimes called the **sacrospinalis** muscles.

- Other muscles of the spine include the **longus capitis** and **longus colli** of the neck and **quadratus lumborum** of the lumbar region.



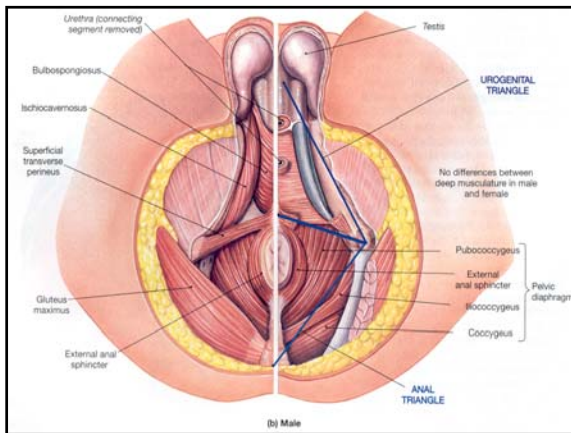
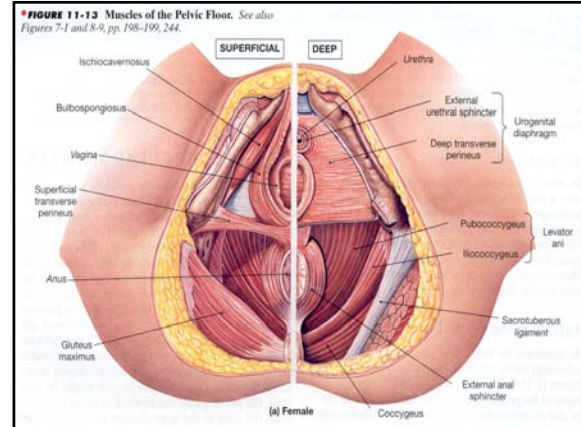
Oblique and Rectus Muscles

- The oblique muscle include the **scalenes** and the **intercostal** and **transversus** muscles. The **external** and **internal intercostals** are important in respiratory movements of the ribs. Also important to respiration is the **diaphragm**.



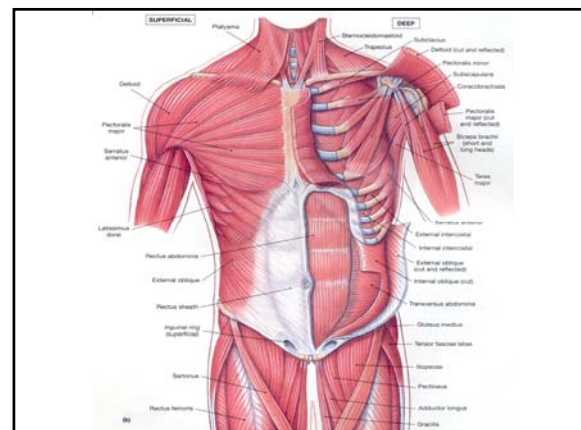
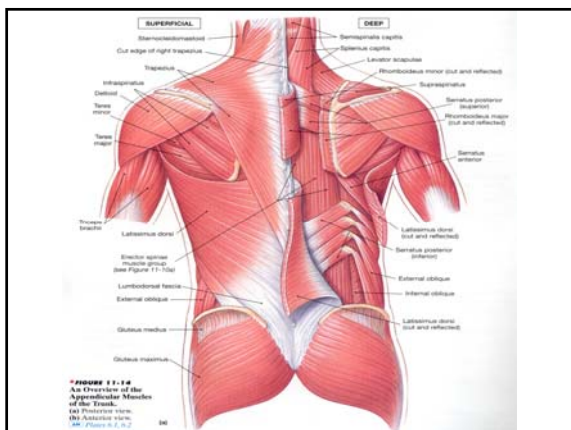
Muscles of the Pelvic Floor

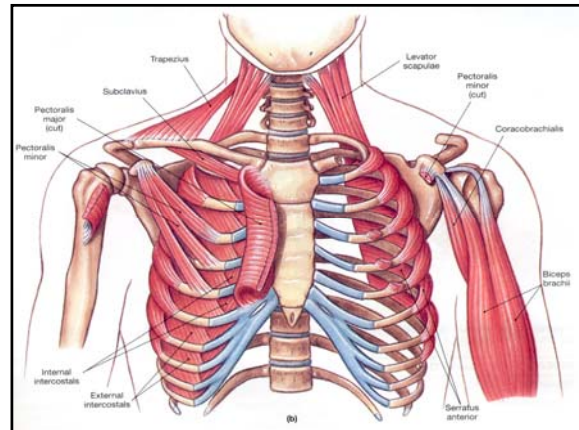
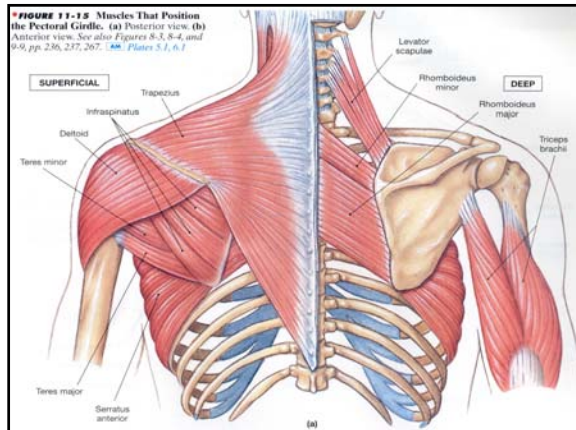
- The **perineum** can be divided into an anterior urogenital triangle and a posterior **anal triangle**. The pelvic floor consists of the **urogenital diaphragm** and the **pelvic diaphragm**.



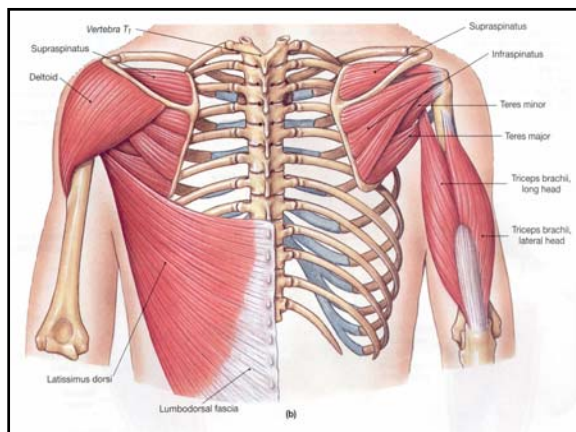
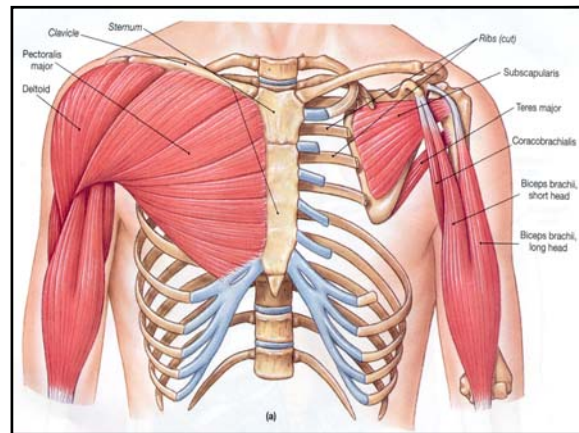
The Appendicular Muscles

- The **trapezius** affects the positions of the shoulder girdle, head, and neck. Other muscles inserting on the scapula include the **rhomboideus**, the **levator scapulae**, the **serratus anterior**, the **subclavius** and the **pectoralis minor**.
- The **deltoid** and **supraspinatus** are important abductors. The **subscapularis** and the **teres major** rotate the arm medially; the **infraspinatus** and **teres minor** perform lateral rotation; and the **coracobrachialis** flexes and adducts the humerus at the shoulder joint.





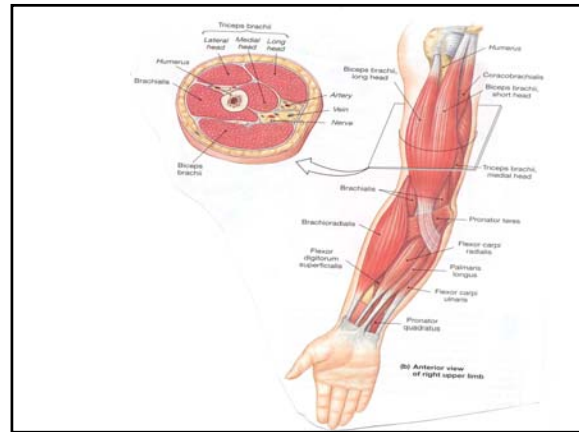
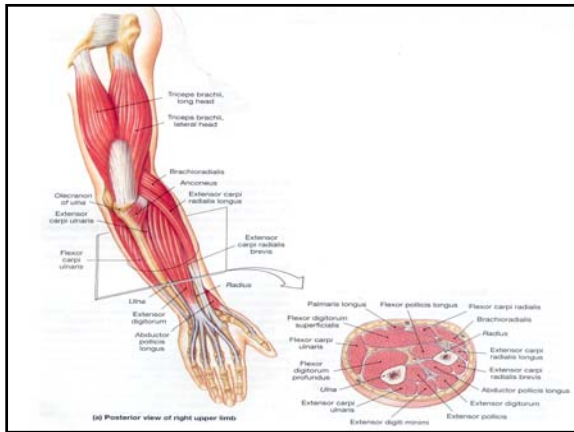
•The **pectoralis major** flexes the humerus at the shoulder joint, and the **latissimus dorsi** extends it.



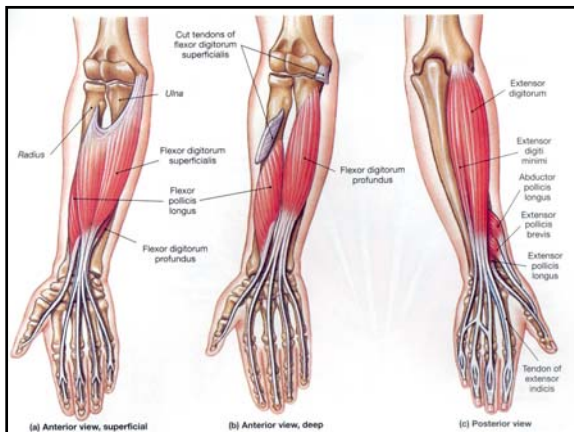
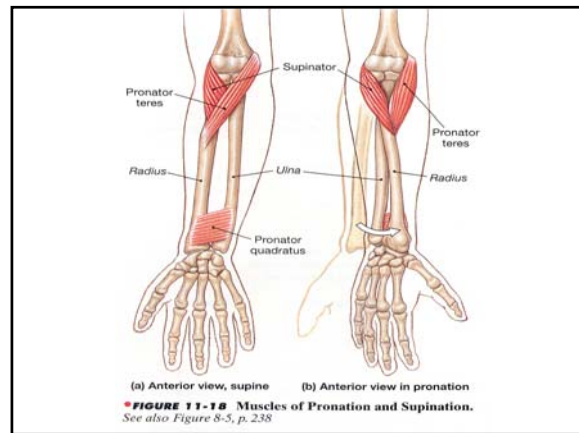
•The primary actions of the **biceps brachii** and the **triceps brachii** (long head) affects the elbow joint. The **brachialis** and **brachioradialis** flex the elbow, opposed by the **anconeus**.

•The flexor **carpi ulnaris**, the flexor **carpi radialis**, and **palmaris longus** cooperate to flex the wrist.

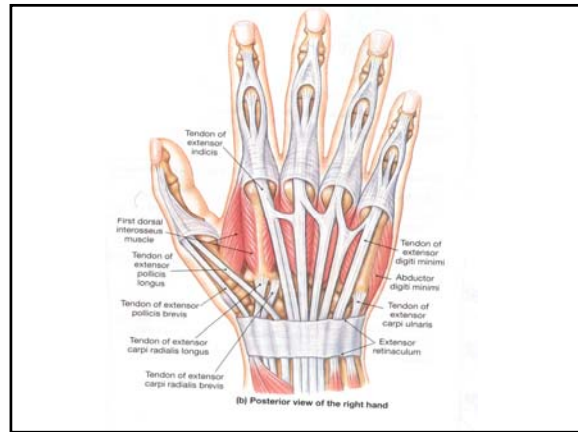
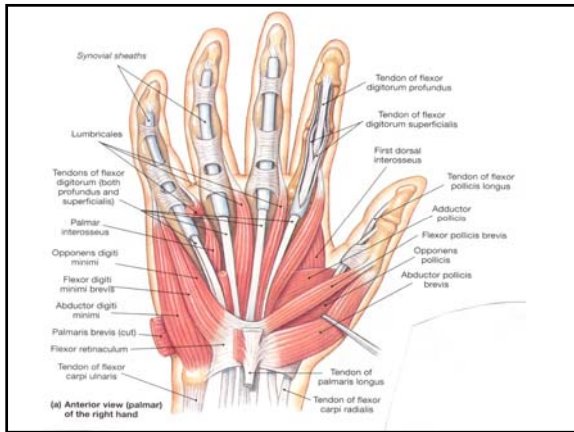
•They are opposed by the **extensor carpi radialis** and **extensor carpi ulnaris**.



•The **pronator teres** and **pronator quadratus** pronate the forearm and are opposed by the **supinator**.

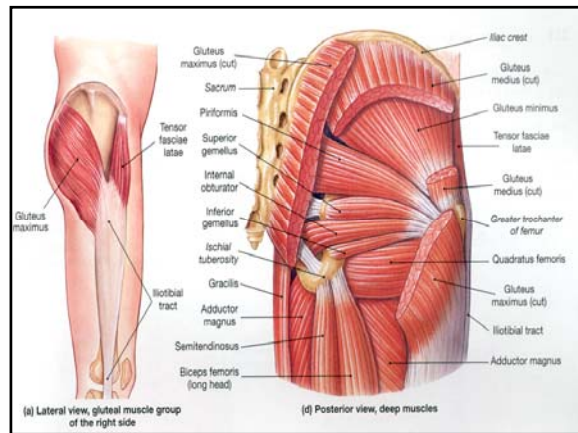


- **Flexor digitorum superficialis:** flexes wrist and middle phalanges of fingers 2-5.
- **Extensor digitorum:** finger extension; extends wrist and abducts (flares) the fingers

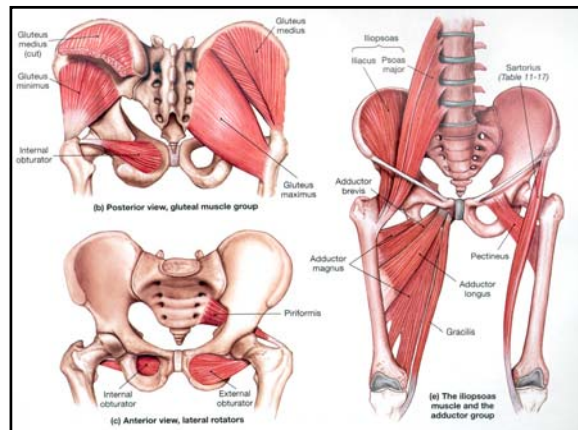


Muscles of the Lower Limbs

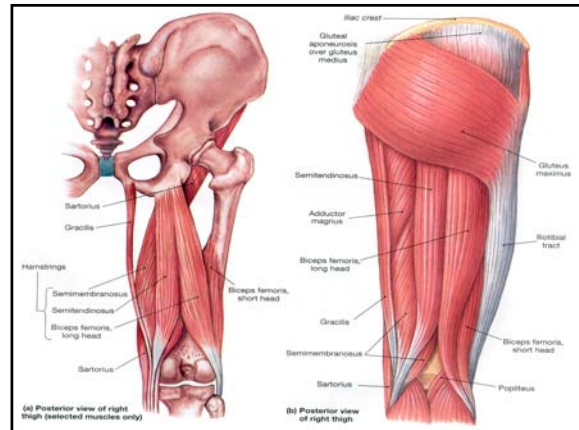
- **Gluteal Muscles** cover the lateral surfaces of the ilia. The largest is the **gluteus maximus**, which shares an insertion with the **tensor fasciae latae**.
- Together these muscles pull on the **iliotibial tract**.



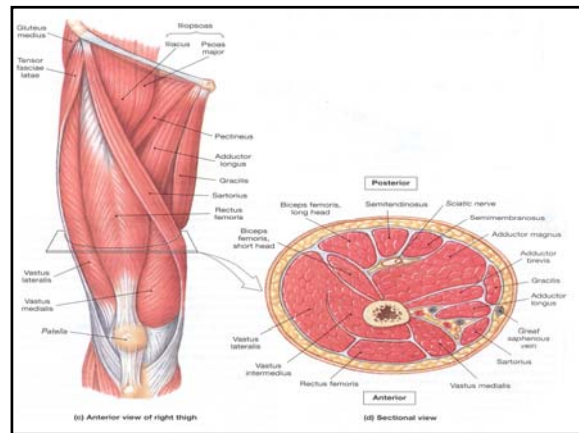
- The **piriformis** and the **obturator** muscles are the most important lateral rotators. The **adductors** can produce a variety of movements.
- The **psaos major** and the **iliacus** merge to form the **iliopsoas** muscle, a powerful flexor of the hip.



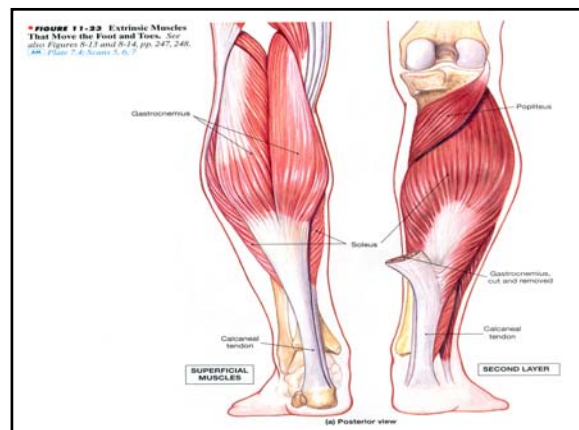
•The flexors of the knee muscle include the **biceps femoris**, **semimembranosus**, and **semitendinosus** (the three **hamstrings**), and the **sartorius**. The **popliteus** unlocks the knee joint.

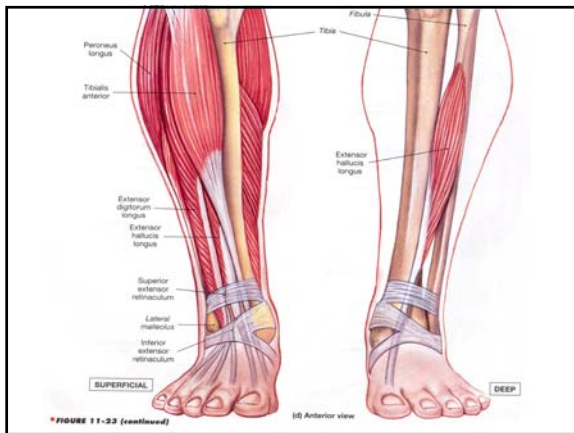
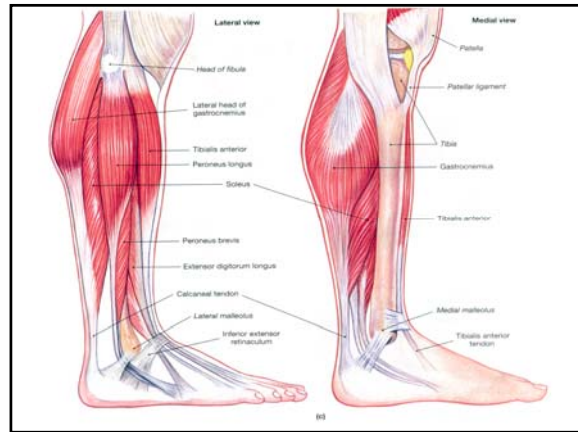
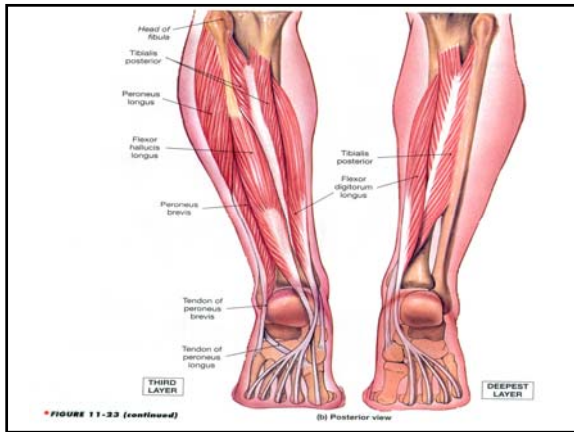


•Collectively the knee extensors are known as the **quadriceps femoris**. This group includes the three **vastus** muscles and the **rectus femoris**.



•The **gastrocnemius** and **soleus** muscles produce plantar flexion. A pair of **peroneus** muscles produce eversion as well as plantar flexion.





Action	Innervation
Extends proximal phalanges of toes 1-4	Deep peroneal nerve (L ₄ -S ₁)
Abducts great toe	Medial plantar nerve (L ₄ -L ₅)
Flexes middle phalange of toes 2-5	As above
Abducts toe 5	Lateral plantar nerve (L ₄ -L ₅)
Flexes toes 2-5	As above
Flexes proximal phalanges; extends middle phalanges; toes 2-5	Medial plantar nerve (L ₄ -L ₅), lateral plantar nerve (2-4)
Flexes proximal phalanx of great toe	Medial plantar nerve (L ₄ -L ₅)
Adducts great toe	Lateral plantar nerve (S ₁ -S ₂)
Flexes proximal phalange of toe 5	As above
Abducts toes	As above
Adducts toes	As above

FIGURE 11-24 Intrinsic Muscles of the Foot. See also Figure 8-14, p. 245. *AM Plate 7.3, Scan 8*
 (d) Dorsal view

